

Case report

Case Report of an Immediately Loaded Double Spire Implant with Cone-Metric Connection in a German Shepherd Dog: Innovations and Long-Term Success

Andrea Palermo¹, Franco Ferrante^{2*}, Ezio Gheno³, Francesca Angiero⁴, Grigore Ion Lazarescu⁵ and Dario Spitaleri⁶

¹Private practice in Lecce, senior clinical lecturer BBP University city of London dental school, UK

²Department of Surgical Medical Sciences and Integrated Diagnostic, University of Genoa, in Genoa, Italy

³Department of Clinical lecturer BBP University city of London dental school, UK

⁴Department of Surgical Medical Sciences and Integrated Diagnostic, University of Genoa, in Genoa, Italy

⁵TituMaiorescu' University, Faculty of Dentistry – Bucharest (Romania)

⁶Private Practice in Udine

Abstract

Aim

The aim of this work was to study the effectiveness and the long-term success of a Double spire conical implant, with a cone metric connection, immediately loaded in a German Shepherd dog.

Materials and Methods

A rehabilitation surgery was performed under general anesthesia of an agenesia of a Premolar tooth in a German Shepherd dog. The animal was carefully followed-up to 2 years.

Results

Following the latest clinical findings, the implant presents itself rehabilitated and 'insitu', and the double coils turn out to be an excellent alternative in terms of success and durability.

Discussion and Conclusion

Our study shows how the innovative double coils implant manufactured by Immediate load and the cone metric connection ensure better transmission of forces of the surrounding bone and a minimally invasive surgical insertion, quick and safe even in the immediate loading.

Keywords: Immediate Load; Dog; Implant Shape.

Introduction

The pressing demand of patients to maintain the aesthetics has led professionals to successfully implement immediate loading also with post-extraction Implants [1,2]. It is to be considered that the immediate loading techniques provide for the rigid connection between the implants in order to obtain an increase in Primary stability, to counteract the rotational movements and evenly distribute the

Forces on them, since subjecting to immediate loading the single implants appear Risky. However, it is shown that the osseous integration is also possible in these Cases [3]. Evidently, other factors contribute to the primary stability by preventing. Those upper micro-motions on the critical threshold for the osseous-

integration (50-150 µm). these factors are: the macroscopic screw drawing, the bi-cortical anchor, The implant length and diameter, the microscopic drawing of the implant surface and the connection between implant and abutment. No less important is the way in which it is realized the provisional implant leaving the crown out of occlusion by subjecting the implants to only masticatory loads [4.5]. In order to speed up Osseous-integration, implants of different shapes and surface characteristics have Been produced up to now: smooth surface implants or with rough surface, implants Subjected to additive-type treatments such as plasma spray coatings made of Titanium or hydroxy-siapatite, or subjected to treatments of the subtractive type, Sandblasting and, more recently, with the acid-etching or a combination of more Treatments. Furthermore, there are the bioactive coatings of the implants which include hydroxy-siapatite and tri-calcium phosphate. These substances are not osseous inductive since they do not determine the growth of bone in ectopic sites, but they are osseous-inductive promoting bone growth that originates from the surrounding bone tissue [1,3].

Materials and Methods

In January 2014, implant rehabilitation was performed in a 3 years old German shepherd dog, weight 37 kg, in good general health.

***Corresponding author:** Franco Ferrante , Department of Surgical Medical Sciences and Integrated Diagnostic, University of Genoa, in Genoa, Italy via Don Cosma 41, Surbo (Lecce), 73010, Italy, Tel: + 39 3334433758; Fax +39 0832366081; E-mail: franco_ferrante@yahoo.it

Sub Date: January 20, 2017, **Acc Date:** February 8, 2017, **Pub Date:** February 14, 2017.

Citation: Andrea Palermo, Franco Ferrante, Ezio Gheno, Francesca Angiero, Grigore Ion Lazarescu and Dario Spitaleri (2017) Case Report of an Immediately Loaded Double Spire Implant with Cone-Metric Connection in a German Shepherd Dog: Innovations and Long-Term Success. BAOJ Dentistry 2: 024.

Copyright: © 2017 Andrea Palermo, et al. This is an open-access article distributed under the terms of the Creative Commons Attribution License, which permits unrestricted use, distribution, and reproduction in any medium, provided the original author and source are credited.

The dog's master reported difficulty in chewing of his animal, especially when eating Foods with dry and hard consistency. Following the execution of latero-lateral radiography (Figure.1), there has been Noticed the absence of a premolar tooth and, in accordance with the Ordinance Law of the Ministry of Health – 12th of December 2006 – and published by the G.U. nr.10 of 13th of January 2007, art.1 – letter E, it was decided to rehabilitate the missing Tooth. For the anesthesia, it was administered the dose of 80 mcg of medetomidine Hydrochloride for each kg of body weight (corresponding to 0.08 ml of the drug / kg of p.v.) And 4 mg of ketamine for each kg of body weight. After the anesthesia, highlighted the edentulous area (Fig 2), it was deemed as suitable the insertion of the implant with appropriate spaces for both the height and the bone thickness.

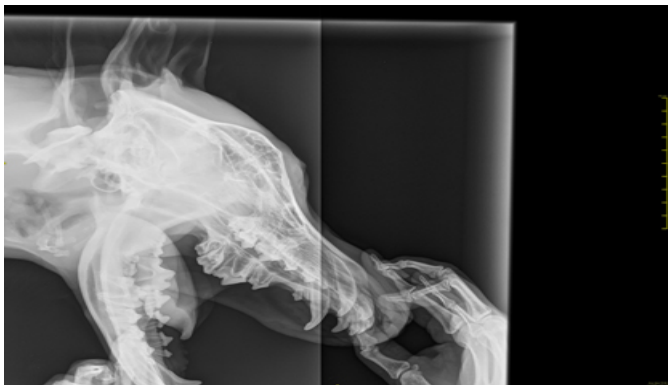

Figure 1: Pre-operative lateral side radiograph

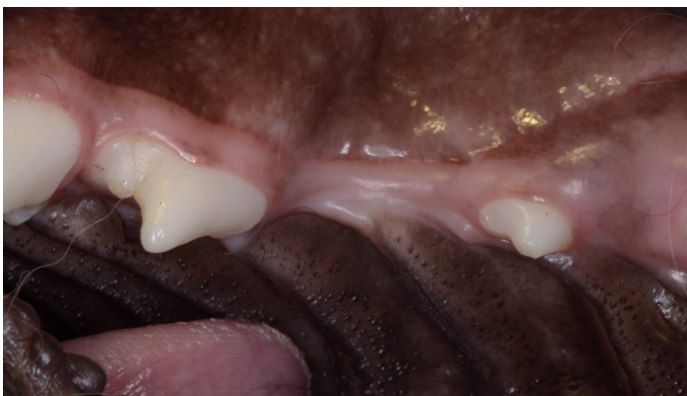

Figure 2: Pre-operative alveolar site

Immediately after the anesthesia, we proceeded with the opening of the full thickness flap and with the preparation of the implant site using drills of increasing diameter up to 5 mm. Once the Immediate load implant was introduced (5 mm x 11.5 mm) (Fig 3), a new Later-lateral control radiographic examination was performed (Fig 4). Subsequently, in the same session, an abutment with conical connection (Fig 5) was placed and the final crown (Fig 6, 7) was cemented for the immediate loading in the same surgical session.

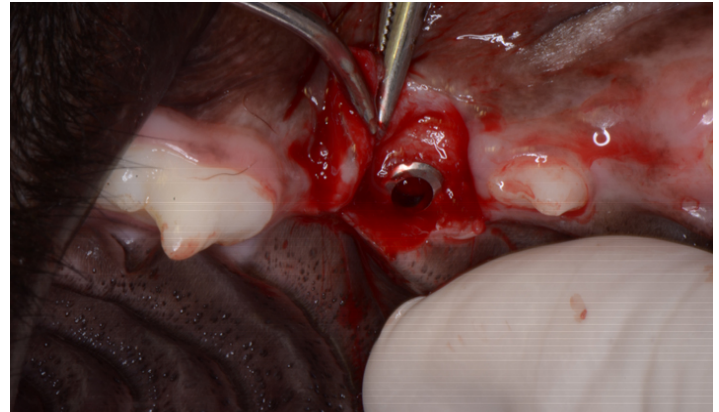


Figure 3: Alveolar site immediately after the implant introduction

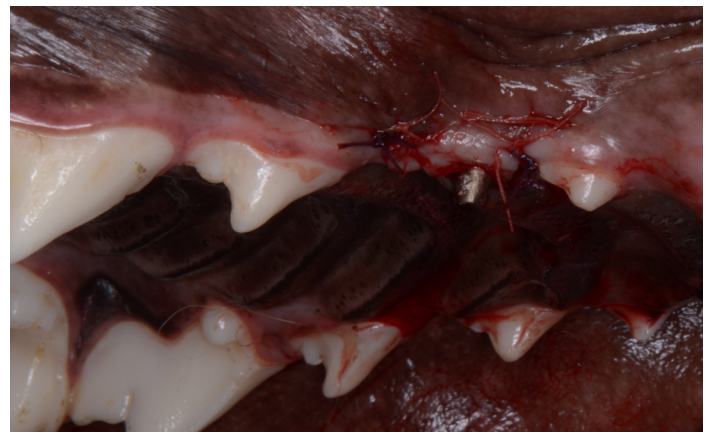

Figure 4: Latero-lateral radiograph after implant surgery

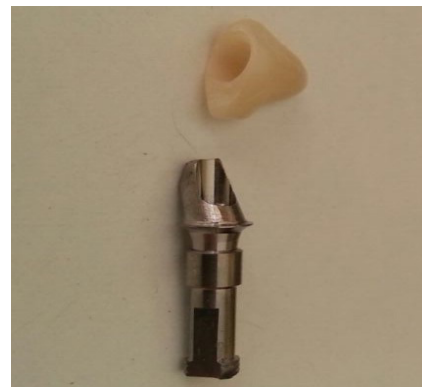

Figure 5: Positioned abutment with cone-metric connection

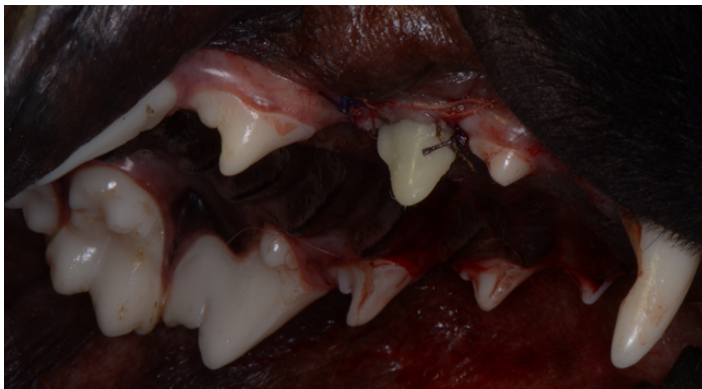


Figure 6: Final prosthesis artefact

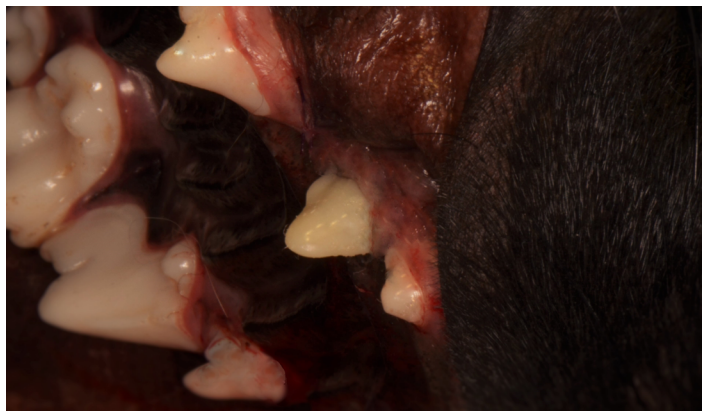

Figure 7: Rehabilitated implant with final prosthetic artefact

In the subsequent weeks, the owner of the animal reported that his German shepherd had not presented any particular problems or complications after the Intervention, but it had only followed a diet based on soft and light food. The veterinary prescribed an antibiotic therapy based on Amoxicillin 250mg tablets, twice a day, for 6 days.

Results

Every six months, up to two years, the German shepherd has been

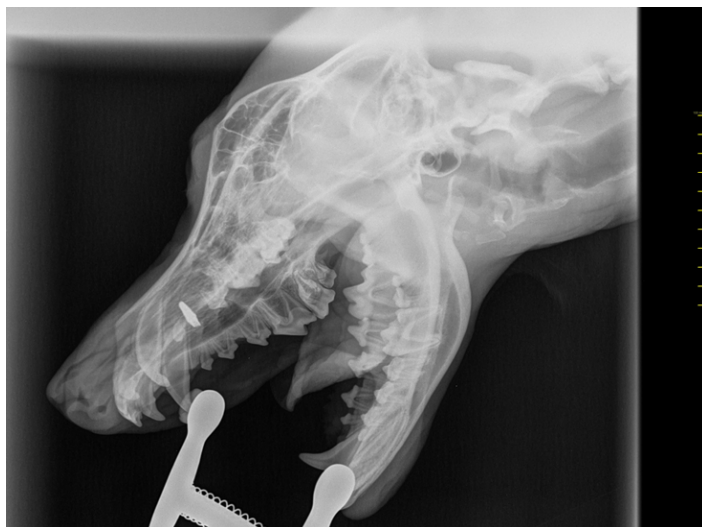

Figure 8: Latero-lateral radiograph after 4 years from surgery

revised so as to get confirmation of the successful osseous-integration with the respective load. There were no contraindications and the German shepherd started right away to feed itself without showing pain or specific problems.

Discussion

The great peculiarity of this article consists in having loaded an implant immediately after its introduction in the mouth and, despite the progressive reduction of the Primary stability with a gradual increase of the secondary stability, it was only from the 21st day after the operation that the success of the clinical case was found and the osseous-integration really occurred.

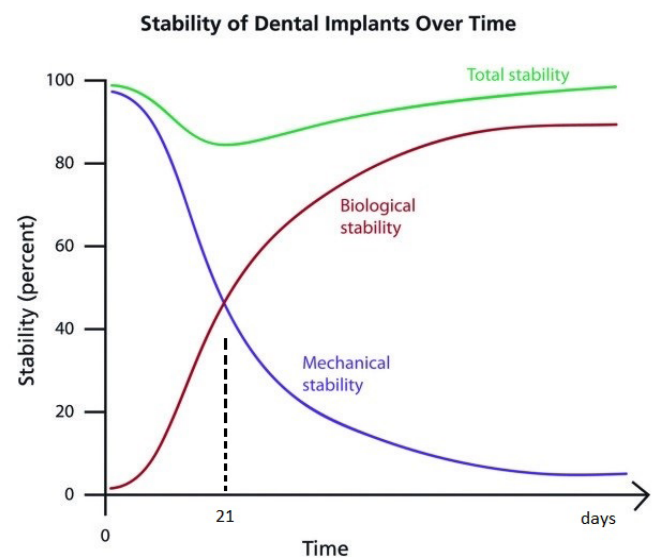


Figure 9: The chart shows the decline of the mechanical stability (primary) in the first weeks, while the biological stability (secondary) is gradually growing. The total stability shows a physiological decline around the 3rd - 4th week.

So as to avoid further stress on the implant site, the biology of post-implantation bone and physiology analysis states that the prosthetic loads should be deferred or, if immediately loaded, it would be safe to advise the patient to have a semi-liquid diet, especially in first month after surgery [3].

The 'Degidi and Piattelli' authors [7] classify load situations in three groups, in Ascending time order: "Early-loading", "non-functional immediate loading", and "Immediate functional loading". Only in the first case of Degidi and Piattelli, the final prosthetic crowns will be delivered in occlusion after 3 weeks from the surgery.

However, in our case report we have further anticipated the "early-loading" because we put the final crown on the same day of the surgery. Obviously, in animals it was not possible providing post-operative instructions and so we can speak of 'essential' immediate loading. This same situation of pure immediate loading is also found in the complex Rehabilitation cases of the lower jaw with the technique of "ALL-ON-FOUR" [8-10]. However, it always refers

to a greater number of implant pillars (with the chance to Give to the patient the right post-operative instructions) and not on the individual Implant in a German shepherd dog [11].

In the light of these observations, the case that occurred in a German shepherd Dog, having a decrease in primary stability, applying a final prosthetic Immediate loading and getting to the resumption of a function right away after surgery, all these aspects surely help to reinforce the importance of a conical connection which has got the right implant design [12] such as the one of the immediate load Company.

Conclusion

The Immediate load Company develops and produces implant devices that can offer High bio-functionality combined with a perfect aesthetic result. The implant surfaces Were studied, designed and built so as to achieve the right balance between Chemical and physical characteristics and speed of the bone integration. After the Completion of the analysis and of the surface set-point, important experiments at a Bioengineering level have been performed in order to optimize the process of bone Remodeling and the correct transfer of loads.

References

1. Ramachandran A, Singh K, Rao J, Mishra N, Jurel SK, et al. (2016) Changes in alveolar bone density Around immediate functionally and non-functionally loaded implants 115(6): 712-717.
2. Glibert M, De Bruyn H, Ostman PO (2016) Six-Year Radiographic, Clinical, and Soft Tissue Outcomes of Immediately Loaded, Straight-Walled, Platform-Switched, Titanium-Alloy Implants with Nano surface Topography. *Int J Oral Maxillofac Implants* 31(1): 167-171.
3. Guida L, Iezzi G, Annunziata M, Salierno A, luorio G, et al. (2008) Immediate placement and loading of dental implants: a human histologic case report 79(3): 575-581.
4. Pozzi A, Mura P (2016) Immediate Loading of Conical Connection Implants: Up-to-2-Year Retrospective Clinical and Radiologic Study. *Int J Oral Maxillofac Implants* 31(1): 142-152.
5. Pimentel Lopes de Oliveira GJ, Leite FC, Pontes AE, Sakakura CE, Junior EM (2016) Comparison of the Primary And Secondary Stability of Implants with Anodized Surfaces and Implants Treated by Acids: A Split-Mouth Randomized Controlled Clinical Trial. *Int J Oral Maxillofac Implants* 31(1):186-190.
6. Bousdras VA, Walboomers F, Jansen JA, Cunningham JL, Blunn G, et al. (2007) Immediate functional loading of single-tooth TiO2 grit-blasted implant Restoration. A controlled prospective study in a porcine model. Part II: Histology and histomorphometry 9(4): 207-216.
7. Degidi M1, Piattelli A (2003) Immediate functional and non-functional loading of dental implants: a 2- to 60-Month follow-up study of 646 titanium implants 74(2): 225-241.
8. Malo P, de Araujo Nobre MA, Lopes AV, Rodrigues R (2015) Immediate loading short implants inserted on low Bone quantity for the rehabilitation of the edentulous maxilla using an All-on-4 design. *J Oral Rehabil* 42(8): 615-623.
9. Malo P, Araujo Nobre MD, Lopes A, Rodrigues R (2015) Double Full-Arch versus Single Full-Arch, Four Implant-Supported Rehabilitations: A Retrospective, 5-Year Cohort Study 24(4): 263-270.
10. Malo P, de Araujo Nobre M, Lopes A, Ferro A, Gravito I (2015) All-on-4® Treatment Concept for the Rehabilitation of the Completely Edentulous Mandible: A 7-Year Clinical and 5-Year Radiographic Retrospective Case Series with Risk Assessment for Implant Failure and Marginal Bone Level. *Clin Implant* 2531-541.
11. Zygogiannis K, Wismeijer D, Aartman IH, Osman RB (2016) A Systematic Review on Immediate Loading of Implants Used to Support Over dentures opposed by Conventional Prosthesis: Factors That Might Influence Clinical Outcomes. *Int J Oral Maxillofac Implants* 31(1): 63-72.
12. Calvo-Guirado JL, Lopez-Lopez PJ, Perez-Albacete Martinez C, Javed F, Granero-Marin JM (2016) Peri-implant bone loss clinical and radiographic evaluation around rough neck and micro thread implants: a 5-year study.